

Point-of-care Ultrasound in Cardiac Arrest

Jonathan A. Paul, D.O., Oliver P. F. Panzer, M.D.

Point-of-care ultrasound is established as a reliable, bedside diagnostic modality for the differentiation of shock, and it is used increasingly during the management of cardiac arrest as well. Because ultrasound machines are accessible in most perioperative and intensive care unit settings and handheld technology is evolving, it has become practical to deploy this tool to the many locations in which arrests occur.

Resuscitation guidelines published by the American Society of Echocardiography (Durham, North Carolina), the American College of Emergency Physicians (Irving, Texas), the European Resuscitation Council (Niel, Belgium), and the American Heart Association (Dallas, Texas) all advocate for the role of point-of-care ultrasound in cardiac arrest, while cautioning clinicians to avoid exceeding 10-s pauses between chest compressions, suggesting that the most experienced clinicians acquire images and acknowledging that more data are required to assess the efficacy of this application.¹⁻³ Because many of the potential causes of cardiac arrest in surgical patients are well suited to sonographic diagnosis, point-of-care ultrasound was added as a distinct step in the pulseless electrical activity/asystole algorithm of the perioperative Advanced Cardiac Life Support (ACLS) guidelines in 2018.⁴

Numerous observational studies and meta-analyses report that focused ultrasound may aid in predicting the return of spontaneous circulation for patients with pulseless electrical activity.⁵⁻¹¹ However, its predictive value for survival after cardiac arrest is uncertain, because in-hospital arrests are relatively uncommon, and data from randomized controlled studies are therefore sparse. Because some evidence suggests that the use of ultrasound may prolong pauses during cardiopulmonary resuscitation (CPR), multiple protocols have been designed with the intent of integrating ultrasound into ACLS safely.¹²⁻²¹ Although each systematic approach strives toward the worthwhile goals of reducing harm and optimizing efficiency, no single approach has been accepted widely as best practice. In this focused clinical review, we describe the role of ultrasound in cardiac arrest rhythm classification, discuss its use in differentiating reversible causes of arrest, provide an overview of protocols, highlight potential pitfalls, and summarize strategies to encourage safe and effective application of ultrasound during ACLS.

Nomenclature

The intended scope of practice described in this article involves point-of-care ultrasound, a qualitative surface

examination of various anatomical locations to screen for a limited number of gross pathologies as indicated by the clinical scenario and as an extension of the physical exam. At times in this review, we use the phrase “focused ultrasound” synonymously. There is potential for other terminology to be confusing in this field, especially that which pertains to cardiac sonography. When applied to imaging of the heart, the American Society of Echocardiography describes focused cardiac ultrasound as a technique involving two-dimensional, grayscale (B-mode) imaging with a limited number of views and performed by someone with basic training in image acquisition and interpretation.^{1,22,23} The term echocardiography, however, is distinct and refers to an advanced ultrasound exam that identifies and quantifies the severity of a broader list of cardiac pathologies using additional modes such as Doppler. As such, although echocardiography may be listed in the names of some protocols for point-of-care ultrasound that we discuss, they are not interchangeable, and our focus is on focused cardiac ultrasound. It is worth noting that although most echocardiograms are consultative, a growing number of acute care clinicians are learning and applying echocardiographic techniques (Doppler modes) in a focused manner. The National Board of Echocardiography (Raleigh, North Carolina) formalized a pathway recently for intensivists to be credentialed in this unique area of critical care echocardiography to answer questions specific to critically ill patients.²⁴ In summary, the cardiac imaging techniques described in this article are basic and therefore can be performed by practitioners with training in any of the aforementioned categories.

Pulseless Electrical Activity *versus* Pseudo-pulseless Electrical Activity

Ultrasound can assist clinicians in identifying the correct rhythm and ACLS management algorithm and in differentiating true pulseless electrical activity from pseudo-pulseless electrical activity. An estimated 80% of in-hospital cardiac arrests consist of nonshockable rhythms,²⁵ for which point-of-care ultrasound has the greatest utility in identifying reversible causes. Pulseless electrical activity can be difficult to distinguish from ventricular fibrillation using the electrocardiogram, and focused ultrasound can provide clarity as long as it does not delay appropriate defibrillation.²⁶⁻²⁸ Even asystole is not a straightforward diagnosis when assessing

This article is featured in “This Month in Anesthesiology,” page A1.

Submitted for publication December 2, 2020. Accepted for publication March 31, 2021. Published online first on May 12, 2021. From the Department of Anesthesiology, Columbia University Medical Center, New York Presbyterian Hospital, New York, New York.

Copyright © 2021, the American Society of Anesthesiologists. All Rights Reserved. Anesthesiology 2021; 135:508-19. DOI: 10.1097/ALN.0000000000003811

rhythm on the monitor; 10 to 35% of patients reported to be in asystole may have cardiac contractility on focused cardiac ultrasound.^{29,30} Pulseless electrical activity is described as an organized rhythm with neither a palpable pulse nor detectable cardiac contractility on ultrasound.⁴ Pseudo-pulseless electrical activity, on the other hand, also has an organized rhythm on electrocardiogram but is distinguished by preserved organized cardiac contractility, although not enough to generate a detectable pulse. Valve motion alone (which can occur with passive flow) should not be mistaken for contractility.

There are data suggesting that the presence of pseudo-pulseless electrical activity is associated with an increased likelihood of achieving return of spontaneous circulation during ACLS.⁸ Two large meta-analyses revealed pooled sensitivities of 77 and 95% and specificities of 80 and 92%, respectively, for return of spontaneous circulation as predicted by cardiac motion on ultrasound.^{9,10} The latter of these reports also suggests that preserved cardiac activity is associated with increased odds of survival to both hospital admission and discharge. However, one recent, retrospective study investigating electrocardiogram and ultrasound findings in adults with nonshockable rhythms indicates that ultrasound may be more useful in predicting mortality than survival.⁶ A prospective, multicenter trial is underway to assess the positive predictive value of the absence of cardiac motion in determining likelihood to achieve return of spontaneous circulation with CPR.⁷ Additional trials are also needed to address the heterogeneity of data regarding predicting survival based upon point-of-care ultrasound findings. In the meantime, ultrasound observations should not be used to make decisions about when to terminate ACLS.

Narrowing the Differential Diagnosis with Ultrasound

ACLS guidelines organize reversible causes of cardiac arrest into the mnemonic of “Hs and Ts.”² Many of the constituent etiologies can be assessed through a history of preceding events (ingestion of toxins, for example) or simple laboratory tests (hyperkalemia, acidosis). Some arrest causes common to the perioperative environment, such as anaphylaxis, local anesthetic systemic toxicity, anesthetic overdose, auto-PEEP (positive end-expiratory pressure), or malignant hyperthermia, are clinical diagnoses. Others, including cardiac tamponade, tension pneumothorax, myocardial ischemia, hypovolemia, acute right ventricular failure, and hypoxia, are all well suited to diagnostic evaluation with ultrasound. Figure 1 illustrates some of the characteristic sonographic findings associated with these problems.

Cardiac Tamponade

The diagnosis of cardiac tamponade is dependent on a high index of suspicion, because signs like jugular vein distention

or pulsus paradoxus are nonspecific and obscured during an arrest. Ultrasound allows quick diagnosis of a pericardial effusion, which prompts consideration of tamponade as the precipitating cause of an arrest. In one small, but prospective observational study, 8 of 12 patients with cardiac motion detected by ultrasound had pericardial effusions observed during ACLS. Three of those patients were diagnosed with tamponade and underwent pericardiocentesis or surgery.³¹ A case report similarly describes an adolescent in pulseless electrical activity arrest 4 weeks after a ventricular septal defect closure, who was found to have a large effusion on ultrasound and had complete recovery after pericardiocentesis.³²

The assessment of pericardial fluid should be made using multiple views. Signs consistent with tamponade, including early diastolic right ventricular collapse and late diastolic and early systolic right atrial collapse, small ventricular chamber sizes, a distended inferior vena cava, and a paradoxical septal shift during spontaneous inspiration, may all be identifiable during an arrest in which there is preserved cardiac activity. Even small effusions, especially those which consist of focal clot, can lead to tamponade physiology. Once tamponade is identified as the likely cause of an arrest, ultrasound can enable needle visualization during pericardiocentesis.^{33,34}

Tension Pneumothorax

A tension pneumothorax occurs when air in the pleural space causes the intrapleural pressure to exceed the atmospheric pressure throughout respiration, leading to reduced venous return and cardiac output. Positive pressure ventilation during general anesthesia and laparoscopic surgery in particular exacerbate this hemodynamic compromise and may increase its likelihood of leading to cardiac arrest.³⁵ Lung ultrasound has excellent specificity for pneumothorax (98.4%) and superior sensitivity to chest radiography^{36,37} and can be performed with the probe positioned apically or laterally during active chest compressions. Visualization of lung sliding, B lines, or lung pulse rules out pneumothorax on the side being evaluated. Point-of-care ultrasound has less sensitivity than specificity for pneumothorax in part because the absence of lung sliding can be attributed to other etiologies such as pleural adhesions or hyperinflation/bullae. However, a lung point, or location at which a region with lung sliding transitions to one without, is a rare but pathognomonic sign of a partial pneumothorax.³⁸ Lung point is a rare finding, and isolated A lines without lung sliding may be adequate to make the presumptive diagnosis if there is a temporal association between the arrest and an event such as penetrating trauma or an invasive procedure performed near the pleura. Sustaining return of spontaneous circulation may require prompt needle decompression and/or chest tube placement.³⁹ Chest compressions

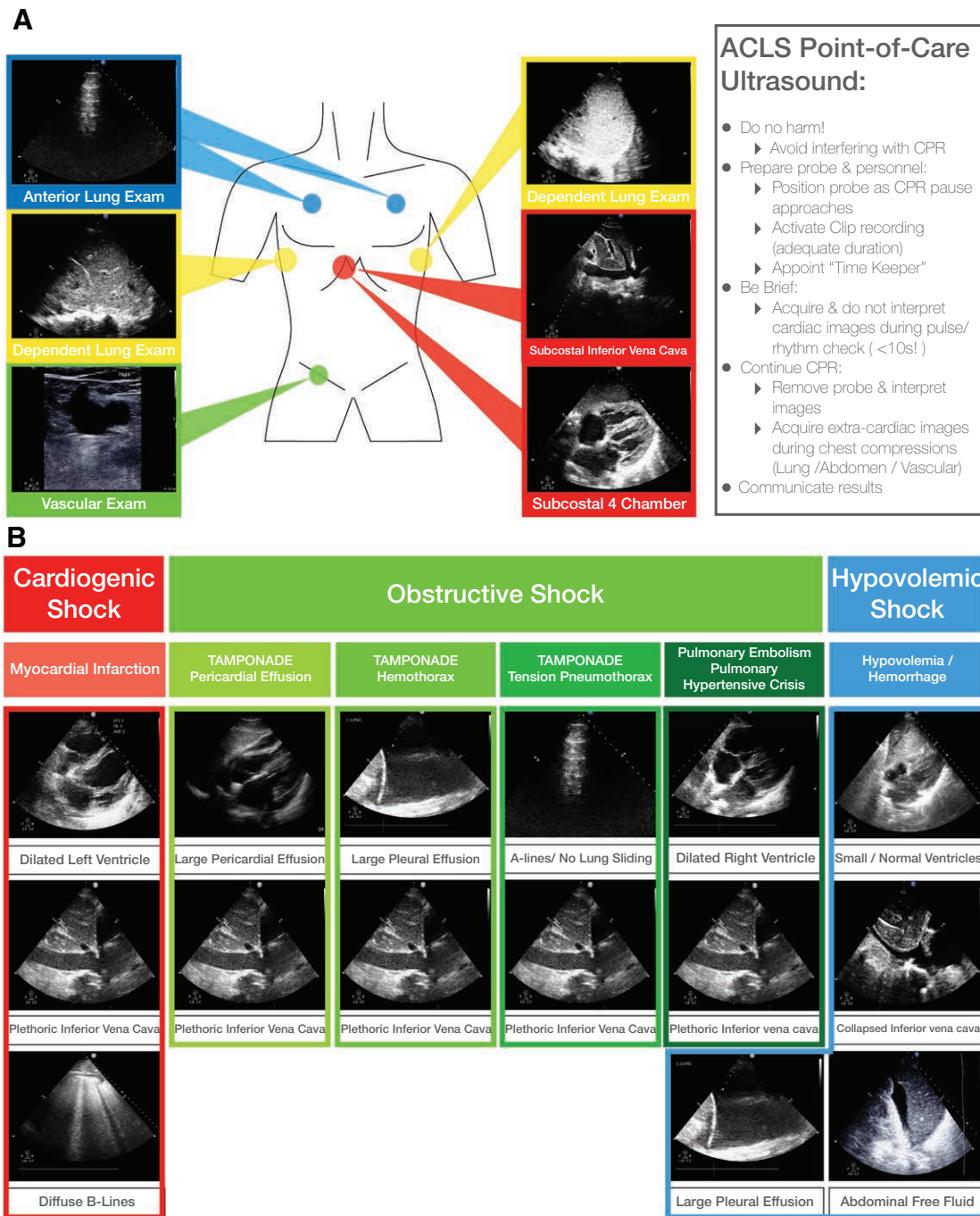


Fig. 1. (A) Example point-of-care ultrasound views that can be obtained during cardiac arrest, including subcostal images (to be obtained during pulse checks) and extracardiac images (which may be obtained alongside active CPR). Also listed (box) are reminders to encourage efficiency and safety. (B) Representative ultrasound images that may be associated with some of the underlying causes of cardiac arrest, organized by the type of shock (cardiogenic, obstructive, or hypovolemic) that may precipitate the arrest. ACLS, Advanced Cardiac Life Support; CPR, cardiopulmonary resuscitation.

themselves can fracture ribs and lead to iatrogenic tension pneumothorax. Point-of-care ultrasound can help evaluate for this complication, especially if a patient deteriorates after initial resuscitation.

Myocardial Infarction

Myocardial ischemia is the most common cause of sudden cardiac death.⁴⁰ Focused cardiac ultrasound can identify

signs of ischemia in the case of pseudo-pulseless electrical activity from acute coronary thrombosis where some cardiac motion is preserved. The presence of severe left or right ventricular hypokinesis raises coronary vasospasm or thrombosis on the differential diagnosis for pulseless electrical activity arrest,^{41,42} although myocardial ischemia is more commonly associated with ventricular tachycardia and fibrillation.^{43,44} After successful resuscitation, the ultrasound exam should be repeated, because the presence of regional wall motion abnormalities may lead to consideration of anticoagulation therapy and cardiology consultation for coronary angiography. Accurate identification of regional wall motion abnormalities falls outside the scope of point-of-care ultrasound, so suspicious findings should be confirmed by practitioners with training in echocardiography and appropriate testing (electrocardiogram, biomarkers). In a patient with recent acute myocardial ischemia, the ultrasound exam may help differentiate sequelae with a grim prognosis, such as left ventricular free wall rupture, from those that may benefit from mechanical intervention, such as papillary muscle rupture causing mitral regurgitation.^{45–48}

Hypovolemia

In the case of pseudo-pulseless electrical activity, but not cardiac standstill, potential signs of hypovolemia may include small ventricular chamber sizes or a collapsed inferior vena cava. This distinction is important, because ventricular chamber size does not always correlate with intravascular volume status; in a prospective study in which 17% of cardiac arrests were attributed to hypovolemia, none of the subjects had collapsed ventricles.⁴⁹ Moreover, in a randomized investigation of induced cardiac arrest in porcine models, the same authors demonstrated that the right ventricle can be dilated in all arrest etiologies, including hypovolemia.⁵⁰

Right atrial pressure can be estimated by measuring inferior vena cava diameter variability throughout the respiratory cycle in a spontaneously breathing patient, and fluid responsiveness can be predicted through similar evaluation in mechanically ventilated patients. However, these calculations are invalidated by excessive minute ventilation, tidal volumes greater than 8 mL/kg, compliance less than 30 cm H₂O, ventilator desynchrony, an open chest or abdomen, and other confounders.^{51–53} In spite of these limitations, if the vena cava is collapsing in a trauma or surgical patient, hemorrhage should be considered. Focused assessment with sonography for trauma can identify free fluid or other acute pathology that may necessitate thoracotomy or laparotomy^{54,55} and has been associated with a mortality benefit in trauma patients.^{56,57}

Acute, Obstructive Right Ventricular Failure

Acute right ventricular failure can lead to cardiac arrest, although discerning which obstructive process (pulmonary

embolism or a pulmonary hypertensive crisis) precipitated the arrest is difficult. Nonspecific but concerning ultrasound signs include right ventricular dilatation in four-chamber and septal flattening in short-axis views, respectively. Reduced right ventricular systolic function as measured by tricuspid annular plane systolic excursion may be appreciated in the first few minutes of an arrest before ventricular equalization occurs. Chronic changes like right ventricular free wall hypertrophy and right atrial dilation make a pulmonary hypertensive crisis more likely, whereas a thin-walled and dilated right ventricle with a normal size right atrium make an acute event like a pulmonary embolism more likely. As stated previously, conclusions based on chamber sizes should be made only if there is preserved cardiac activity and not in cases of true pulseless electrical activity or asystole.

Pulmonary embolism is a common cause of pulseless electrical activity. In one prospective, observational study of 25 patients in cardiac arrest with nonshockable rhythms, 9 were found to have pulmonary embolism (8 confirmed through transesophageal echocardiography [TEE] and 1 confirmed by autopsy).⁵⁸ Surface ultrasound rarely leads to direct visualization of pulmonary artery thrombus. Even when performed and interpreted by practitioners with advanced training, the sensitivity for pulmonary embolism is only 29% using right ventricular dilatation, 51% using right ventricular dysfunction, and 52 to 56% with the combination of both.^{59,60} Consequently, the American Society of Echocardiography has stated explicitly that acute pulmonary embolism cannot be ruled out with echocardiography.⁶¹ Still, visualization of the aforementioned findings during a point-of-care ultrasound exam should prompt a scan of lower extremity veins for deep vein thrombosis. Lower extremity scanning can take place during chest compressions and evidence of clot warrants a risk/benefit discussion about empiric anticoagulation or thrombolytic therapy if computed tomography angiography is not feasible after return of spontaneous circulation is achieved. In the absence of deep vein thrombosis, it is important to keep other causes of acute right ventricular failure in mind, such as gas or fat emboli during procedures known to carry elevated risk for these events.

Hypoxia

Respiratory insufficiency is the underlying cause of 15 to 40% of in-hospital cardiac arrests.^{25,62} Severe, untreated hypoxia commonly leads to bradycardia and eventually pulseless electrical activity. Once a secure airway has been established and controlled mechanical ventilation with adequate fractional inspired oxygen tension provided, ultrasound can be deployed to investigate the precipitating cause of hypoxia if it is not intuitive. Diffuse B lines on lung ultrasound are nonspecific, because they may be observed in diverse disease states including acute respiratory distress

syndrome and decompensated heart failure. On the other hand, focal B lines, combined with signs of pleural effusion (hypoechoic fluid collection or a positive spine sign) or consolidation (tissue-like sign or dynamic air bronchograms) will provide clues to guide therapy after successful resuscitation. Patients with large pleural effusions may benefit from ultrasound-guided thoracentesis.

Protocols for Point-of-care Ultrasound during Cardiac Arrest

It is imperative that the ultrasound examination complement, and not interfere with, standard ACLS. Numerous protocols exist, all aspiring to operationalize an approach to point-of-care ultrasound during cardiac arrest. Most are the result of expert opinion, and a subset have undergone evaluation with prospective trials. Table 1 lists each protocol's scanning focus, sequence, personnel involved, and distinguishing features.

Early protocols focused on assessment of the heart alone, whereas subsequent approaches promote a more complete exam alongside CPR. In spite of a limited scope, the first protocol for ultrasound during cardiac arrest, labeled Focused Echocardiographic Evaluation in Resuscitation (FEER),¹³ was novel in detailing a step-wise algorithm and in describing seminal elements that remain important today (including the incorporation of an independent timekeeper). However, this algorithm permits interpreting and giving a description of findings during the pulse check, which may delay resuming chest compressions. The same authors also developed the Focused Echocardiography Entry Level (FEEL) protocol,²¹ a training program for emergency medicine, critical care, and anesthesiology clinicians. A prospective, observational trial of patients undergoing prehospital ACLS found that using focused cardiac ultrasound allowed identification of pseudo-pulseless electrical activity and other findings that altered management in 78% of subjects.²⁹

A series of additional protocols expanded upon its principles by encouraging the scanning of multiple anatomic locations for findings that might aid in identifying reversible causes for an arrest. For example, the Cardiac Arrest Ultrasound Exam (CAUSE)¹⁶ and Cardiac Arrest Sonographic Assessment (CASA)¹⁵ protocols were unique in recommending lung and abdominal evaluations, respectively. Later, the pulseless electrical activity protocol (PEA, a mnemonic for Pulmonary, Epigastric, Abdomen/additional scanning regions)²⁰ and the Sequential Echocardiographic Scanning Assessing MEchanism or origin of severe shock of indistinct cause (SESAME) protocol^{17,63} added to a growing list of published methods for applying comprehensive ultrasound during cases of both severe shock and cardiac arrest. Two potential problems emerged as a result of the creation of myriad protocols within a short time frame. First, the variation in anatomical scanning order could be confusing to prospective learners (table 1). One protocol,

for example begins with pulmonary, vascular, and abdominal exams (suggesting that they can be completed in under 40s), but there is likely greater diagnostic yield from imaging the heart first during an arrest.⁶³ Second, more emphasis was needed on efficiency and safety. A prospective, interventional study demonstrated that pulse checks associated with an ultrasound exam were significantly shorter after a protocol implementation.⁶⁴ However, the median duration still exceeded 10s in both study groups.

More recent protocols have recognized that it is prudent to only acquire images during pauses from CPR and to defer image interpretation and extracardiac scanning until chest compressions have resumed. A special interest group of the International Federation for Emergency Medicine (West Melbourne, Australia) provided a consensus statement with a protocolized approach to Sonography in Hypotension and Cardiac Arrest (SHoC).¹² This methodology instructs the sonographer to evaluate four "Fs" (fluid, form, function, and filling) with a tiered set of views. The mandatory, core evaluation assesses pericardial fluid, ventricular form, and function (pseudo-pulseless electrical activity *vs.* true pulseless electrical activity/asystole). Optional supplemental and additional views may assess for pleural effusions, pneumothorax, or peritoneal free fluid concerning for hemorrhage. Similarly, the Echocardiographic Assessment using Subcostal-only view in Advanced Life Support (EASy-ALS) protocol includes a prerequisite training course and is built on using only one acoustic window for cardiac imaging and a novel description of shock phenotypes with corresponding suggestions for initial therapies.⁶⁵

Implementing Point-of-care Ultrasound Safely

Appropriate concern has been expressed about point-of-care ultrasound during cardiac arrest, citing the potential for its application to interfere with CPR.⁶⁶ Prospective, cohort studies of cardiac arrest in emergency department settings suggest that ultrasound use may be associated with an increased duration of pulse checks.^{67,68} However, when point-of-care ultrasound was performed by an ultrasound-trained attending in the second of these investigations, the median pulse check time was only 4s. Although it is best to have the most experienced clinician acquire images during ACLS, interpreting them does not require significant expertise. In cardiac arrest simulations, resident physicians trained in focused ultrasound were capable of diagnosing management-altering pathologies within a timeframe similar to that of board-certified cardiologists.⁶⁹

A systematic approach is critical to minimize CPR interruption and avoid patient harm. Each of the protocols for point-of-care ultrasound in cardiac arrest described above have limitations, and randomized controlled trials are needed before any individual methodology can be recommended for routine implementation. Still, there are select components of these protocols that warrant emphasizing.

Table 1. Unique Elements of Existing Protocols for Point-of-care Ultrasound Application during Cardiac Arrest

Protocol	Year Published	Scanning Focus	Sequence Details	Personnel (Distinct from ACLS Team)	Distinguishing Features
Focused Echocardiographic Evaluation in Resuscitation (FEER)	2007	Cardiac	10-step algorithm, with 4 cyclical phases: 1. Preparation 2. Image acquisition during pulse check (<10 s) 3. Resume CPR 4. Image interpretation, communication, and action	Trained physician; timekeeper	Applicable in both cardiac arrest and severe shock; timekeeper counts out loud during pulse check exam
Focused Echocardiographic Entry Level (FEEL)	2009	Cardiac	Same sequence as FEER	Trained physician	Assessment limited to cardiac motion, ventricular size and function, and pericardial fluid; prospective, observational study of protocol performed in 2010
Cardiac Arrest Ultrasound Exam (CAUSE)	2007	Cardiac and pulmonary	1. Subcostal view during chest compressions 2. Other cardiac views during pulse check (<10 s) 3. Lung ultrasound thereafter	Trained physician	Focused on detecting possible effusion, hypovolemia, pulmonary embolism, and pneumothorax
Cardiac Arrest Sonographic Assessment (CASA)	2018	Cardiac and pulmonary and abdominal	Evaluate for specific diagnoses in sequential pulse checks (<10 s): 1. Tamponade 2. Right heart strain 3. Organized cardiac activity 4. Lung and abdominal ultrasound during active CPR	Trained physician; timekeeper	Timekeeper counts out loud during pulse check exam; interventional trial demonstrated acceptable pulse check duration
Pulmonary, Epigastric, and Abdomen/additional scans (PEA)	2010	Cardiac and pulmonary and abdominal and vascular	In spite of acronym order, sequence begins with epigastric (subcostal) imaging that informs further ultrasound evaluation	Trained physician	Applicable in both cardiac arrest and severe shock
Sequential Echocardiographic Scanning Assessing MEchanism or Origin of Severe Shock of Indistinct Cause (SESAME)	2015	Cardiac and pulmonary and abdominal and vascular	1. Lung (rule out pneumothorax, apply other lung ultrasound protocols) 2. Vascular (assess for deep vein thrombosis) 3. Abdomen (free fluid) 4. Pericardium (effusion) 5. Other cardiac evaluation	Trained physician	Atypical scanning sequence; emphasizes role of ultrasound in guiding therapies during resuscitation
Sonography in Hypotension and Cardiac Arrest (SHoC)	2017	Cardiac and pulmonary and abdominal and vascular	"4-F" (Fluid, Form, Function, Filling) diagnostic approach in the following scanning order: 1. Core cardiac views 2. Supplementary views (inferior vena cava, lung) 3. Additional views (abdomen/pelvis, vascular, airway)	Trained physician	Applicable in both cardiac arrest and severe shock; protocol developed as part of consensus statement by International Federation of Emergency Medicine Operational checklist
Echocardiographic Assessment using Subcostal-only view in Advanced Life Support (EASy-ALS)	2020	Cardiac and pulmonary and abdominal and vascular	After initial 2 min of CPR, cardiac exam performed from subcostal view during sequential pulse checks (<10 s); additional images can be acquired from extracardiac locations during active CPR, without interfering with chest compressions	Trained physician; timekeeper	Describes set of unique, sonographic phenotypes of shock that can aid in recognizing and treating reversible causes of arrest

ACLS, Advanced Cardiac Life Support; CPR, cardiopulmonary resuscitation.

Point-of-care ultrasound staff are an integral part of the ACLS team and thus need to communicate effectively with the team leader and recorder throughout the resuscitation process. Essential personnel include the most experienced sonographer for scanning and a timekeeper for CPR pauses. Detailed preparation is necessary: upon arrival to an arrest, plug in and power on equipment, choose a phased array probe with appropriate preset/depth/gain, and program the video clip duration to at least 10 s. The sonographer should

be in position, with gel applied and probe ready in the subcostal space, as the opportunity for pulse check nears. Acquire cardiac images during pulse checks, waiting to interpret those images and perform additional, extracardiac thoracic, abdominal, and vascular scanning after chest compressions have resumed. The subcostal four-chamber view is the preferred starting point for cardiac imaging, although other standardized views may be attempted if needed in subsequent pulse checks. During pauses, the timekeeper

counts seconds out loud using a digital timer. Announce findings and discuss potential interventions with the team. Repeat the ultrasound exam after return of spontaneous circulation is achieved to guide therapy. Finally, one of our goals as perioperative clinicians is to prevent deterioration to cardiac arrest. Ultrasound exams should be performed for patients with significant hemodynamic instability of unclear etiology in the postanesthesia care unit and intensive care unit to identify possible interventions that may prevent further decompensation. Such preemptive scanning can also inform the team whether the patient has imaging windows that are conducive to rapid image acquisition.

One auxiliary role for cardiac sonography from the subcostal view during CPR may be to confirm that the hand position for chest compressions is maximizing cardiac output, in conjunction with end-tidal carbon dioxide monitoring. Although it is common practice to position one's hands at the inter nipple line, in a study of 189 patients who had undergone computed tomography of the chest, the structure under the inter nipple line was either the aortic root, left ventricular outflow tract, or ascending aorta in 80% of subjects.⁷⁰ Similarly, it has been demonstrated with TEE during ACLS that the maximal area of compression was the aorta in 78% of subjects⁷¹ and that stroke volume increases as the compression site is shifted to the xyphoid process. Another common problem during standard resuscitation efforts is the false positive or negative detection of return of spontaneous circulation by pulse palpation. An inability to detect a pulse, when present, may be secondary to severe hypotension, body habitus, or insensate fingertips. Conversely, the clinician may mistakenly confuse her/his own pulse with the patient's. A pediatric study reported sensitivity of 86% and specificity of 68% for pulse palpation during cardiac arrest,⁷² and there is also evidence that successful carotid pulse detection depends on adequate neck extension.⁷³ A recent study found that focused ultrasound was superior to both manual palpation and Doppler assessment in pulse recognition,⁷⁴ illustrating another indirect benefit to ultrasound use during ACLS.

When transthoracic cardiac ultrasound is ineffective because of the presence of surgical drains, subcutaneous air, or other impediments, TEE may be advantageous if performed by a qualified clinician. There is growing popularity for TEE use in the emergency department during CPR,^{75,76} and credentialed anesthesiologists and intensivists are often available during perioperative arrests. TEE can be performed without interrupting active resuscitation and can identify many of the same precipitating causes of an arrest as surface ultrasound.^{77,78} In a video-based assessment of 139 pulse check periods, TEE use was associated with shorter CPR pauses.⁷⁹ With careful patient selection, TEE is also safe; in 7,200 patients undergoing intraoperative TEE, there was only 0.2% morbidity and 0.0% mortality observed.⁸⁰ Relative disadvantages of TEE include the need to wait for endotracheal intubation and the inability to perform

a complete pulmonary exam or image the abdomen and lower extremities. Therefore, TEE may be a useful addition to, but not replacement for, surface ultrasound during cardiac arrest.

Discussion

Point-of-care ultrasound is a valuable tool for confirming rhythm classification, detecting preserved cardiac activity, and narrowing the differential diagnosis for reversible causes of cardiac arrest so that appropriate therapies can be initiated. Focused ultrasound is endorsed for these purposes by the most recent ACLS guidelines and is included as a distinct step in the nonshockable algorithm for perioperative ACLS. With adequate expertise and precautions, it is possible to implement point-of-care ultrasound safely without interfering with CPR.

One historical barrier to broad adoption has been accessibility of ultrasound technology to the teams that respond to cardiac arrests. Because many hospitals now have at least a small number of ultrasound machines with a phased array probe available for use in their operating rooms and postanesthesia care units, transport delays should be on the order of minutes (which are spent initiating compressions or delivering early defibrillation as appropriate) before the first pulse checks when ultrasound is of greatest utility. However, expedient deployment of these machines during an emergency is contingent on departmental policies and systems that promote equipment being stored in and returned to central locations with consistency. The same may not always be true for arrests throughout the hospital, but there is opportunity for anesthesiologists and resuscitation teams from other services to leverage portable tablet- or smartphone-compatible ultrasound devices during ACLS in remote hospital sites.

Further study is needed to evaluate the relative efficacy of available protocols for this application of point-of-care ultrasound. In a randomized trial, Atkinson *et al.*⁸¹ did not observe a survival benefit nor a change in secondary outcomes. However, their investigation was limited to patients in undifferentiated shock, not cardiac arrest,⁸¹ and it was only powered to detect a 10% mortality reduction, which may have been an unrealistic goal.⁸² Another trial randomized 100 patients in cardiac arrest to ACLS with point-of-care ultrasound or standard ACLS and, although it did not find that ultrasound was associated with increased survival, it was also not powered to detect a clinically significant difference.⁸³ Most protocols were evaluated through studies suggesting some improvement in outcomes, but they are small and observational in design. The EASy-ALS approach incorporates commendable safety measures and a novel classification system for severe shock and cardiac arrest etiologies, and a multicenter, prospective study of its application in surgical patients is in development. Because there are countless variables conflating survival as an outcome

measure, future randomized trials may consider evaluating whether ultrasound has an effect on more specific endpoints such as the identification of reversible causes of arrest leading to therapies that enable sustained resuscitation. Performance bias in these investigations could be reduced by ensuring that study personnel who assess subjective outcome data are blinded and that any staff who cannot be blinded to the ultrasound exam evaluate objective outcomes only.

In addition to collecting outcome data for point-of-care ultrasound in cardiac arrest and determining the relative efficacy of protocols, continued efforts to provide training for this tool to not only residents and fellows but also attending anesthesiologists and surgeons are critical. Given that we are intimately familiar with our patients' histories and the events that precede perioperative cardiac arrests, we are already adept at developing hypotheses about underlying etiologies. Focused ultrasound offers us a powerful tool to further refine our differential and tailor therapies for successful resuscitation.

Acknowledgments

The authors are forever grateful to the late and beloved Desmond Jordan, M.D., for his lifelong mentorship and education, always challenging us to become better physicians. The authors thank Nibras Bughrara, M.B.Ch.B., Department of Anesthesiology, Albany Medical Center, Albany, New York, for past insights and for ongoing collaboration in this field.

Research Support

Support was provided solely from institutional and/or departmental sources.

Competing Interests

The authors declare no competing interests.

Correspondence

Address correspondence to Dr. Panzer: 630 West 168th Street, PH-5, New York, New York 10032. op2015@cumc.columbia.edu. ANESTHESIOLOGY's articles are made freely accessible to all readers on www.anesthesiology.org, for personal use only, 6 months from the cover date of the issue.

References

1. Labovitz AJ, Noble VE, Bierig M, Goldstein SA, Jones R, Kort S, Porter TR, Spencer KT, Tayal VS, Wei K: Focused cardiac ultrasound in the emergent setting: A consensus statement of the American Society of Echocardiography and American College of Emergency Physicians. *J Am Soc Echocardiogr* 2010; 23:1225–30
2. Link MS, Berkow LC, Kudenchuk PJ, Halperin HR, Hess EP, Moitra VK, Neumar RW, O'Neil BJ, Paxton JH, Silvers SM, White RD, Yannopoulos D, Donnino MW: Part 7: Adult Advanced Cardiovascular Life Support: 2015 American Heart Association guidelines update for cardiopulmonary resuscitation and emergency cardiovascular care. *Circulation* 2015; 132:S444–64
3. Soar J, Nolan JP, Böttiger BW, Perkins GD, Lott C, Carli P, Pellis T, Sandroni C, Skrifvars MB, Smith GB, Sunde K, Deakin CD; Adult Advanced Life Support Section Collaborators: European Resuscitation Council Guidelines for Resuscitation 2015: Section 3. Adult advanced life support. *Resuscitation* 2015; 95:100–47
4. Moitra VK, Einav S, Thies KC, Nunnally ME, Gabrielli A, Maccioli GA, Weinberg G, Banerjee A, Ruetzler K, Dobson G, McEvoy MD, O'Connor MF: Cardiac arrest in the operating room: Resuscitation and management for the anesthesiologist: Part 1. *Anesth Analg* 2018; 126:876–88
5. Atkinson PR, Beckett N, French J, Banerjee A, Fraser J, Lewis D: Does point-of-care ultrasound use impact resuscitation length, rates of intervention, and clinical outcomes during cardiac arrest?: A study from the Sonography in Hypotension and Cardiac Arrest in the Emergency Department (SHoC-ED) investigators. *Cureus* 2019; 11:e4456
6. Beckett N, Atkinson P, Fraser J, Banerjee A, French J, Talbot JA, Stoica G, Lewis D: Do combined ultrasound and electrocardiogram-rhythm findings predict survival in emergency department cardiac arrest patients?: The Second Sonography in Hypotension and Cardiac Arrest in the Emergency Department (SHoC-ED2) study. *CJEM* 2019; 21:739–43
7. Javaudin F, Pes P, Montassier E, Legrand A, Ordureau A, Volteau C, Arnaudet I, Le Conte P: Early point-of-care focused echocardiographic asystole as a predictive factor for absence of return of spontaneous circulatory in out-of-hospital cardiac arrests: A study protocol for a prospective, multicentre observational study. *BMJ Open* 2019; 9:e027448
8. Kedan I, Ciozda W, Palatinus JA, Palatinus HN, Kimchi A: Prognostic value of point-of-care ultrasound during cardiac arrest: A systematic review. *Cardiovasc Ultrasound* 2020; 18:1
9. Lalonde E, Burwash-Brennan T, Burns K, Atkinson P, Lambert M, Jarman B, Lamprecht H, Banerjee A, Woo MY; SHoC Investigators: Is point-of-care ultrasound a reliable predictor of outcome during atraumatic, non-shockable cardiac arrest?: A systematic review and meta-analysis from the SHoC investigators. *Resuscitation* 2019; 139:159–66
10. Tsou PY, Kurbedin J, Chen YS, Chou EH, Lee MG, Lee MC, Ma MH, Chen SC, Lee CC: Accuracy of point-of-care focused echocardiography in predicting outcome of resuscitation in cardiac arrest patients: A systematic review and meta-analysis. *Resuscitation* 2017; 114:92–9

11. Wu C, Zheng Z, Jiang L, Gao Y, Xu J, Jin X, Chen Q, Zhang M: The predictive value of bedside ultrasound to restore spontaneous circulation in patients with pulseless electrical activity: A systematic review and meta-analysis. *PLoS One* 2018; 13:e0191636
12. Atkinson P, Bowra J, Milne J, Lewis D, Lambert M, Jarman B, Noble VE, Lamprecht H, Harris T, Connolly J; Members of the International Federation of Emergency Medicine Sonography in Hypotension and Cardiac Arrest working group: International Federation for Emergency Medicine Consensus Statement: Sonography in hypotension and cardiac arrest (SHoC): An international consensus on the use of point of care ultrasound for undifferentiated hypotension and during cardiac arrest: Corrigendum. *CJEM* 2017; 19:327
13. Breikreutz R, Walcher F, Seeger FH: Focused echocardiographic evaluation in resuscitation management: Concept of an advanced life support-conformed algorithm. *Crit Care Med* 2007; 35:S150–61
14. Flato UA, Paiva EF, Carballo MT, Buehler AM, Marco R, Timerman A: Echocardiography for prognostication during the resuscitation of intensive care unit patients with non-shockable rhythm cardiac arrest. *Resuscitation* 2015; 92:1–6
15. Gardner KF, Clattenburg EJ, Wroe P, Singh A, Mantuani D, Nagdev A: The Cardiac Arrest Sonographic Assessment (CASA) exam: A standardized approach to the use of ultrasound in PEA. *Am J Emerg Med* 2018; 36:729–31
16. Hernandez C, Shuler K, Hannan H, Sonyika C, Likourezos A, Marshall J: C.A.U.S.E.: Cardiac arrest ultra-sound exam: A better approach to managing patients in primary non-arrhythmogenic cardiac arrest. *Resuscitation* 2008; 76:198–206
17. Lichtenstein D, Malbrain ML: Critical care ultrasound in cardiac arrest. Technological requirements for performing the SESAME-protocol: A holistic approach. *Anaesthesiol Intensive Ther* 2015; 47:471–81
18. Niendorff DF, Rassias AJ, Palac R, Beach ML, Costa S, Greenberg M: Rapid cardiac ultrasound of inpatients suffering PEA arrest performed by nonexpert sonographers. *Resuscitation* 2005; 67:81–7
19. Price S, Uddin S, Quinn T: Echocardiography in cardiac arrest. *Curr Opin Crit Care* 2010; 16:211–5
20. Testa A, Cibinel GA, Portale G, Forte P, Giannuzzi R, Pignataro G, Silveri NG: The proposal of an integrated ultrasonographic approach into the ALS algorithm for cardiac arrest: The PEA protocol. *Eur Rev Med Pharmacol Sci* 2010; 14:77–88
21. Breikreutz R, Uddin S, Steiger H, Ilper H, Steche M, Walcher F, Via G, Price S: Focused echocardiography entry level: New concept of a 1-day training course. *Minerva Anesthesiol* 2009; 75:285–92
22. Spencer KT, Kimura BJ, Korcarz CE, Pellikka PA, Rahko PS, Siegel RJ: Focused cardiac ultrasound: Recommendations from the American Society of Echocardiography. *J Am Soc Echocardiogr* 2013; 26:567–81
23. Via G, Hussain A, Wells M, Reardon R, ElBarbary M, Noble VE, Tsung JW, Neskovic AN, Price S, Oren-Grinberg A, Liteplo A, Cordioli R, Naqvi N, Rola P, Poelaert J, Gulić TG, Sloth E, Labovitz A, Kimura B, Breikreutz R, Masani N, Bowra J, Talmor D, Guarracino F, Goudie A, Xiaoting W, Chawla R, Galderisi M, Blaivas M, Petrovic T, Storti E, Neri L, Melniker L; International Liaison Committee on Focused Cardiac UltraSound (ILC-FoCUS); International Conference on Focused Cardiac UltraSound (IC-FoCUS): International evidence-based recommendations for focused cardiac ultrasound. *J Am Soc Echocardiogr* 2014; 27:683.e1–33
24. Díaz-Gómez JL, Frankel HL, Hernandez A: National certification in critical care echocardiography: Its time has come. *Crit Care Med* 2017; 45:1801–4
25. Andersen LW, Holmberg MJ, Berg KM, Donnino MW, Granfeldt A: In-hospital cardiac arrest: A review. *JAMA* 2019; 321:1200–10
26. Amaya SC, Langsam A: Ultrasound detection of ventricular fibrillation disguised as asystole. *Ann Emerg Med* 1999; 33:344–6
27. Blaivas M, Fox JC: Outcome in cardiac arrest patients found to have cardiac standstill on the bedside emergency department echocardiogram. *Acad Emerg Med* 2001; 8:616–21
28. Querellou E, Meyran D, Petitjean F, Le Dreff P, Maurin O: Ventricular fibrillation diagnosed with trans-thoracic echocardiography. *Resuscitation* 2009; 80:1211–3
29. Breikreutz R, Price S, Steiger HV, Seeger FH, Ilper H, Ackermann H, Rudolph M, Uddin S, Weigand MA, Müller E, Walcher F; Emergency Ultrasound Working Group of the Johann Wolfgang Goethe-University Hospital, Frankfurt am Main: Focused echocardiographic evaluation in life support and peri-resuscitation of emergency patients: A prospective trial. *Resuscitation* 2010; 81:1527–33
30. Gaspari R, Weekes A, Adhikari S, Noble VE, Nomura JT, Theodoro D, Woo M, Atkinson P, Blehar D, Brown SM, Caffery T, Douglass E, Fraser J, Haines C, Lam S, Lanspa M, Lewis M, Liebmann O, Limkakeng A, Lopez F, Platz E, Mendoza M, Minnigan H, Moore C, Novik J, Rang L, Scruggs W, Raio C: Emergency department point-of-care ultrasound in out-of-hospital and in-ED cardiac arrest. *Resuscitation* 2016; 109:33–9
31. Tayal VS, Kline JA: Emergency echocardiography to detect pericardial effusion in patients in PEA and near-PEA states. *Resuscitation* 2003; 59:315–8
32. Steiger HV, Rimbach K, Müller E, Breikreutz R: Focused emergency echocardiography: Lifesaving tool for a 14-year-old girl suffering out-of-hospital pulseless electrical activity arrest because of cardiac tamponade. *Eur J Emerg Med* 2009; 16:103–5

33. Silvestry FE, Kerber RE, Brook MM, Carroll JD, Eberman KM, Goldstein SA, Herrmann HC, Homma S, Mehran R, Packer DL, Parisi AF, Pulerwitz T, Seward JB, Tsang TS, Wood MA: Echocardiography-guided interventions. *J Am Soc Echocardiogr* 2009; 22:213–31; quiz 316–7
34. Tsang TS, Enriquez-Sarano M, Freeman WK, Barnes ME, Sinak LJ, Gersh BJ, Bailey KR, Seward JB: Consecutive 1127 therapeutic echocardiographically guided pericardiocenteses: Clinical profile, practice patterns, and outcomes spanning 21 years. *Mayo Clin Proc* 2002; 77:429–36
35. Roberts DJ, Leigh-Smith S, Faris PD, Blackmore C, Ball CG, Robertson HL, Dixon E, James MT, Kirkpatrick AW, Kortbeek JB, Stelfox HT: Clinical presentation of patients with tension pneumothorax: A systematic review. *Ann Surg* 2015; 261:1068–78
36. Alrajab S, Youssef AM, Akkus NI, Caldito G: Pleural ultrasonography *versus* chest radiography for the diagnosis of pneumothorax: review of the literature and meta-analysis. *Crit Care* 2013; 17:R208
37. Alrajhi K, Woo MY, Vaillancourt C: Test characteristics of ultrasonography for the detection of pneumothorax: A systematic review and meta-analysis. *Chest* 2012; 141:703–8
38. Lichtenstein DA, Mezière G, Lascols N, Biderman P, Courret JP, Gepner A, Goldstein I, Tenoudji-Cohen M: Ultrasound diagnosis of occult pneumothorax. *Crit Care Med* 2005; 33:1231–8
39. Kenny L, Teasdale R, Marsh M, McElnay P: Techniques of training in the management of tension pneumothorax: Bridging the gap between confidence and competence. *Ann Transl Med* 2016; 4:233
40. Priori SG, Blomström-Lundqvist C, Mazzanti A, Blom N, Borggrefe M, Camm J, Elliott PM, Fitzsimons D, Hatala R, Hindricks G, Kirchhof P, Kjeldsen K, Kuck KH, Hernandez-Madrid A, Nikolaou N, Norekvål TM, Spaulding C, Van Veldhuisen DJ; ESC Scientific Document Group: 2015 ESC Guidelines for the management of patients with ventricular arrhythmias and the prevention of sudden cardiac death: The Task Force for the Management of Patients with Ventricular Arrhythmias and the Prevention of Sudden Cardiac Death of the European Society of Cardiology (ESC). Endorsed by: Association for European Paediatric and Congenital Cardiology (AEPC). *Eur Heart J* 2015; 36:2793–867
41. Osada M, Tanaka Y, Komai T, Maeda Y, Kitano M, Oishi M, Masui K, Nakazawa S, Tamura K: Successful resuscitation using nitroglycerin for refractory pulseless electrical activity in intensive care unit. *Intensive Care Med* 2000; 26:255
42. Yasue H, Nakagawa H, Itoh T, Harada E, Mizuno Y: Coronary artery spasm—clinical features, diagnosis, pathogenesis, and treatment. *J Cardiol* 2008; 51:2–17
43. Bigger JT Jr, Dresdale FJ, Heissenbuttel RH, Weld FM, Wit AL: Ventricular arrhythmias in ischemic heart disease: Mechanism, prevalence, significance, and management. *Prog Cardiovasc Dis* 1977; 19:255–300
44. Zimetbaum PJ, Josephson ME: Use of the electrocardiogram in acute myocardial infarction. *N Engl J Med* 2003; 348:933–40
45. Bresson D, Girerd N, Bouali A, Turc J, Bonnefoy E: Pulseless electrical activity after myocardial infarction: Not always a left ventricular free wall rupture. *Am J Emerg Med* 2013; 31:267.e5–7
46. Figueras J, Curós A, Cortadellas J, Soler-Soler J: Reliability of electromechanical dissociation in the diagnosis of left ventricular free wall rupture in acute myocardial infarction. *Am Heart J* 1996; 131:861–4
47. Tavakoli R, Weber A, Vogt P, Brunner HP, Pretre R, Turina M: Surgical management of acute mitral valve regurgitation due to post-infarction papillary muscle rupture. *J Heart Valve Dis* 2002; 11:20–6
48. Yip HK, Wu CJ, Chang HW, Wang CP, Cheng CI, Chua S, Chen MC: Cardiac rupture complicating acute myocardial infarction in the direct percutaneous coronary intervention reperfusion era. *Chest* 2003; 124:565–71
49. Aagaard R, Løfgren B, Grøfte T, Sloth E, Nielsen RR, Frederiksen CA, Granfeldt A, Bøtker MT: Timing of focused cardiac ultrasound during advanced life support: A prospective clinical study. *Resuscitation* 2018; 124:126–31
50. Aagaard R, Granfeldt A, Bøtker MT, Mygind-Klausen T, Kirkegaard H, Løfgren B: The right ventricle is dilated during resuscitation from cardiac arrest caused by hypovolemia: A porcine ultrasound study. *Crit Care Med* 2017; 45:e963–70
51. Brennan JM, Blair JE, Goonewardena S, Ronan A, Shah D, Vasaiwala S, Kirkpatrick JN, Spencer KT: Reappraisal of the use of inferior vena cava for estimating right atrial pressure. *J Am Soc Echocardiogr* 2007; 20:857–61
52. Kircher BJ, Himelman RB, Schiller NB: Noninvasive estimation of right atrial pressure from the inspiratory collapse of the inferior vena cava. *Am J Cardiol* 1990; 66:493–6
53. Natori H, Tamaki S, Kira S: Ultrasonographic evaluation of ventilatory effect on inferior vena caval configuration. *Am Rev Respir Dis* 1979; 120:421–7
54. Rozycki GS, Ballard RB, Feliciano DV, Schmidt JA, Pennington SD: Surgeon-performed ultrasound for the assessment of truncal injuries: Lessons learned from 1540 patients. *Ann Surg* 1998; 228:557–67
55. Rozycki GS, Feliciano DV, Ochsner MG, Knudson MM, Hoyt DB, Davis F, Hammerman D, Figueredo V, Harviel JD, Han DC, Schmidt JA: The role of ultrasound in patients with possible penetrating cardiac wounds: A prospective multicenter study. *J Trauma* 1999; 46:543–52

56. Plummer D, Brunette D, Asinger R, Ruiz E: Emergency department echocardiography improves outcome in penetrating cardiac injury. *Ann Emerg Med* 1992; 21:709–12
57. Symbas NP, Bongiorno PF, Symbas PN: Blunt cardiac rupture: The utility of emergency department ultrasound. *Ann Thorac Surg* 1999; 67:1274–6
58. Comess KA, DeRook FA, Russell ML, Tognazzi-Evans TA, Beach KW: The incidence of pulmonary embolism in unexplained sudden cardiac arrest with pulseless electrical activity. *Am J Med* 2000; 109:351–6
59. Bova C, Greco F, Misuraca G, Serafini O, Crocco F, Greco A, Noto A: Diagnostic utility of echocardiography in patients with suspected pulmonary embolism. *Am J Emerg Med* 2003; 21:180–3
60. Miniati M, Monti S, Pratali L, Di Ricco G, Marini C, Formichi B, Prediletto R, Michelassi C, Di Lorenzo M, Tonelli L, Pistolesi M: Value of transthoracic echocardiography in the diagnosis of pulmonary embolism: Results of a prospective study in unselected patients. *Am J Med* 2001; 110:528–35
61. Douglas PS, Khandheria B, Stainback RF, Weissman NJ, Brindis RG, Patel MR, Khandheria B, Alpert JS, Fitzgerald D, Heidenreich P, Martin ET, Messer JV, Miller AB, Picard MH, Raggi P, Reed KD, Rumsfeld JS, Steimle AE, Tonkovic R, Vijayaraghavan K, Weissman NJ, Yeon SB, Brindis RG, Douglas PS, Hendel RC, Patel MR, Peterson E, Wolk MJ, Allen JM; American College of Cardiology Foundation Quality Strategic Directions Committee Appropriateness Criteria Working Group; American Society of Echocardiography; American College of Emergency Physicians; American Society of Nuclear Cardiology; Society for Cardiovascular Angiography and Interventions; Society of Cardiovascular Computed Tomography; Society for Cardiovascular Magnetic Resonance; American College of Chest Physicians; Society of Critical Care Medicine: ACCF/ASE/ACEP/ASNC/SCAI/SCCT/SCMR 2007 appropriateness criteria for transthoracic and transesophageal echocardiography: A report of the American College of Cardiology Foundation Quality Strategic Directions Committee Appropriateness Criteria Working Group, American Society of Echocardiography, American College of Emergency Physicians, American Society of Nuclear Cardiology, Society for Cardiovascular Angiography and Interventions, Society of Cardiovascular Computed Tomography, and the Society for Cardiovascular Magnetic Resonance endorsed by the American College of Chest Physicians and the Society of Critical Care Medicine. *J Am Coll Cardiol* 2007; 50:187–204
62. Perman SM, Stanton E, Soar J, Berg RA, Donnino MW, Mikkelsen ME, Edelson DP, Churpek MM, Yang L, Merchant RM; American Heart Association's Get With the Guidelines®—Resuscitation (formerly the National Registry of Cardiopulmonary Resuscitation) Investigators: Location of in-hospital cardiac arrest in the United States: Variability in event rate and outcomes. *J Am Heart Assoc* 2016; 5:e003638
63. Lichtenstein DA: How can the use of lung ultrasound in cardiac arrest make ultrasound a holistic discipline?: The example of the SESAME-protocol. *Med Ultrason* 2014; 16:252–5
64. Clattenburg EJ, Wroe PC, Gardner K, Schultz C, Gelber J, Singh A, Nagdev A: Implementation of the Cardiac Arrest Sonographic Assessment (CASA) protocol for patients with cardiac arrest is associated with shorter CPR pulse checks. *Resuscitation* 2018; 131:69–73
65. Bughrara N, Herrick SL, Leimer E, Sirigaddi K, Roberts K, Pustavoitau A: Focused cardiac ultrasound and the periresuscitative period: A case series of resident-performed echocardiographic assessment using subcostal-only view in advanced life support. *A A Pract* 2020; 14:e01278
66. Moskowitz A, Berg KM: First do no harm: Echocardiography during cardiac arrest may increase pulse check duration. *Resuscitation* 2017; 119:A2–3
67. Huis In't Veld MA, Allison MG, Bostick DS, Fisher KR, Goloubeva OG, Witting MD, Winters ME: Ultrasound use during cardiopulmonary resuscitation is associated with delays in chest compressions. *Resuscitation* 2017; 119: 95–98
68. Clattenburg EJ, Wroe P, Brown S, Gardner K, Losonczy L, Singh A, Nagdev A: Point-of-care ultrasound use in patients with cardiac arrest is associated prolonged cardiopulmonary resuscitation pauses: A prospective cohort study. *Resuscitation* 2018; 122:65–8
69. Greenstein YY, Martin TJ, Rolnitzky L, Felner K, Kaufman B: Goal-directed transthoracic echocardiography during Advanced Cardiac Life Support: A pilot study using simulation to assess ability. *Simul Healthc* 2015; 10:193–201
70. Shin J, Rhee JE, Kim K: Is the inter-nipple line the correct hand position for effective chest compression in adult cardiopulmonary resuscitation? *Resuscitation* 2007; 75:305–10
71. Hwang SO, Zhao PG, Choi HJ, Park KH, Cha KC, Park SM, Kim SC, Kim H, Lee KH: Compression of the left ventricular outflow tract during cardiopulmonary resuscitation. *Acad Emerg Med* 2009; 16:928–33
72. Tibballs J, Russell P: Reliability of pulse palpation by healthcare personnel to diagnose paediatric cardiac arrest. *Resuscitation* 2009; 80:61–4
73. Ochoa FJ, Ramalle-Gómara E, Carpintero JM, García A, Saralegui I: Competence of health professionals to check the carotid pulse. *Resuscitation* 1998; 37:173–5
74. Zengin S, Gümüşboğa H, Sabak M, Eren ŞH, Altunbas G, Al B: Comparison of manual pulse palpation, cardiac ultrasonography and Doppler ultrasonography

- to check the pulse in cardiopulmonary arrest patients. *Resuscitation* 2018; 133:59–64
75. Blaivas M: Transesophageal echocardiography during cardiopulmonary arrest in the emergency department. *Resuscitation* 2008; 78:135–40
 76. Fair J, Mallin M, Mallemat H, Zimmerman J, Arntfield R, Kessler R, Bailitz J, Blaivas M: Transesophageal echocardiography: Guidelines for point-of-care applications in cardiac arrest resuscitation. *Ann Emerg Med* 2018; 71:201–7
 77. Memtsoudis SG, Rosenberger P, Loffler M, Eltzschig HK, Mizuguchi A, Shernan SK, Fox JA: The usefulness of transesophageal echocardiography during intraoperative cardiac arrest in noncardiac surgery. *Anesth Analg* 2006; 102:1653–7
 78. van der Wouw PA, Koster RW, Delemarre BJ, de Vos R, Lampe-Schoenmaeckers AJ, Lie KI: Diagnostic accuracy of transesophageal echocardiography during cardiopulmonary resuscitation. *J Am Coll Cardiol* 1997; 30:780–3
 79. Fair J III, Mallin MP, Adler A, Ockerse P, Steenblik J, Tonna J, Youngquist ST: Transesophageal echocardiography during cardiopulmonary resuscitation is associated with shorter compression pauses compared with transthoracic echocardiography. *Ann Emerg Med* 2019; 73:610–6
 80. Kallmeyer IJ, Collard CD, Fox JA, Body SC, Shernan SK: The safety of intraoperative transesophageal echocardiography: A case series of 7200 cardiac surgical patients. *Anesth Analg* 2001; 92:1126–30
 81. Atkinson PR, Milne J, Diegelmann L, Lamprecht H, Stander M, Lussier D, Pham C, Henneberry R, Fraser JM, Howlett MK, Mekwan J, Ramrattan B, Middleton J, van Hoving DJ, Peach M, Taylor L, Dahn T, Hurley S, MacSween K, Richardson LR, Stoica G, Hunter S, Olszynski PA, Lewis DA: Does point-of-care ultrasonography improve clinical outcomes in emergency department patients with undifferentiated hypotension?: An international randomized controlled trial From the SHoC-ED investigators. *Ann Emerg Med* 2018; 72:478–89
 82. Brunet M, Chaplin T: Does point-of-care ultrasonography improve clinical outcomes in emergency department patients with undifferentiated hypotension? *CJEM* 2019; 21:593–4
 83. Chardoli M, Heidari F, Rabiee H, Sharif-Alhoseini M, Shokoohi H, Rahimi-Movaghar V: Echocardiography integrated ACLS protocol *versus* conventional cardiopulmonary resuscitation in patients with pulseless electrical activity cardiac arrest. *Chin J Traumatol* 2012; 15:284–7